


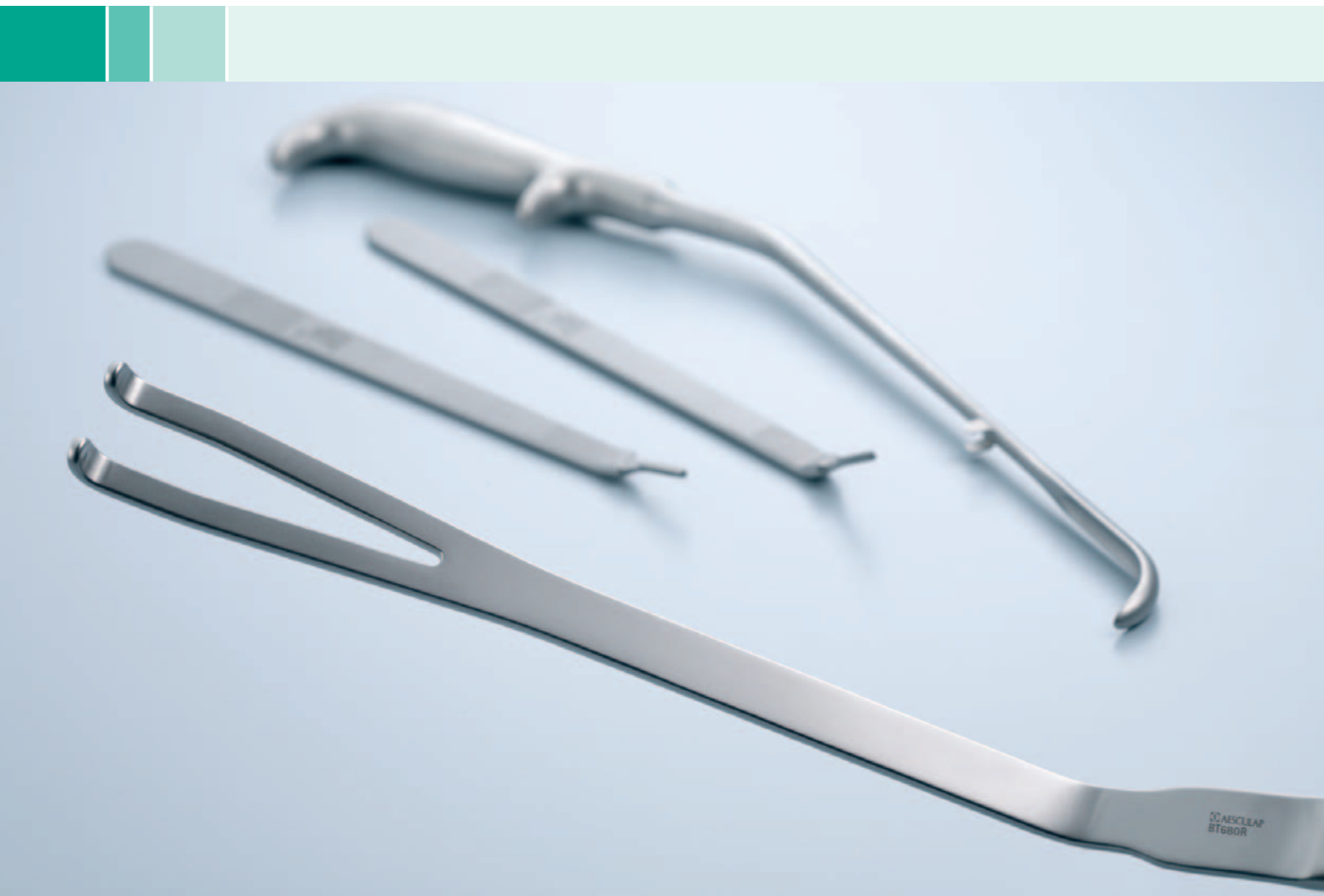
# Aesculap® Barré-Instruments

Instruments for Radical prostatectomy



Surgical Instruments

# Barré-Instruments



## ■ | Content

1. Introduction	4
2. General recommendations	5
3. Surgical technique	6
3.1 Incision and exposure	6
3.2 Exposure of the prostate apex	6
3.3 Preservation of the striated sphincter	7
3.4 Nerve sparing	10
3.5 Dissection of the seminal vesicles and section of the bladder neck	12
3.6 Excision of the seminal vesicles	13
3.7 Visual inspection of the specimen	13
3.8 Vesicourethral anastomosis	14
4. References	15
5. Instruments	16
6. Index	26

# Barré-Instruments

## Introduction



### Surgery in Motion

#### "Open Radical Retropubic Prostatectomy"

Dr. Christian Barré, Clinique Jules Verne, Nantes, France

Eur Urol. 2007 Jul;52(1):71-80. Epub 2006 Dec 11.

We describe a surgical procedure for radical retropubic prostatectomies that we have used in a prospective series of 231 patients with localised prostate cancer (mean age 63 yr; range 46-75 yr). Nerve-sparing was performed in 148 of 231 patients. We insist on three points: (1) high-quality preservation of the sphincter, with the sphincter divided to keep its anatomic environment intact; (2) high-precision retrograde dissection of the neurovascular bundles in the mid-gland prostate zone for early recovery of erectile function (the dissection of the bundles is described for each prostate zone [apex, mid-gland, base]); and (3) the need to standardise each step of the procedure for a reproducible protocol independent of individual patient anatomy. These three measures will ensure the best cancer control with the best functional results. The rate of positive margins for patients with organ-confined (pT2) cancer was 3.7% (2.4% related to an invaded striated sphincter). The quality of the excised specimens was further checked by noting the frequency of capsular incision (2.6%) and of inked benign prostatic glands (2.6%). By 12 mo, 94% of patients were fully continent and 70.5% had recovered the ability to maintain an erection for satisfactory sexual intercourse without the need for medication.

## General recommendations

Parameter	Recommendation
Patient positioning	Place patient in dorsal decubitus position. Tilt the operating table at umbilicus level. Above the umbilicus, the patient's body should be in the Trendelenburg position forming an angle of about 30° with the lower part of the body which remains horizontal [7].
Instruments	Use specialised instrument: prostatic retractor, urethral retractor, dorsal vein complex clamp, nerve-sparing dissector, nerve-sparing scissors, long, angled scalpels (0°, 12°, 25°).
Bleeding control	Maintain mean arterial BP between 55 and 65 mm Hg during nerve sparing for a bloodless operating field if no cardiovascular or hepatic.



# Barré-Instruments

## Surgical technique

We describe the steps of an RP protocol developed on the basis of a personal series of >1500 RPs and characterised by: (1) high-quality preservation of the sphincter within its anatomic environment, using a surgical knife and not scissors for high-precision dissection; (2) retrograde dissection of the neurovascular bundles; and (3) a standard procedure for each step of the RP, thus yielding a reproducible protocol independent of individual patient anatomy.

## Incision and exposure

- Perform a conventional incision and exposure. Perform a bilateral pelvic lymphadenectomy except in patients with low Gleason grade biopsies (<4) or with a prostate-specific antigen (PSA) level <10 ng/ml [8].

## Exposure of the prostate apex

- Make an incision in the endopelvic fascia extending from the prostate base to the puboprostatic ligament (Fig. 1a). Transect the puboprostatic ligaments.
- Free the levator ani muscle fibres at the prostate apex. This is a more delicate manoeuvre because of the depth of dissection, the thickness of the fibres, and the presence of venous pedicles originating from the pelvic sidewall (Fig. 1b and c).
- Dissect similarly on both sides.

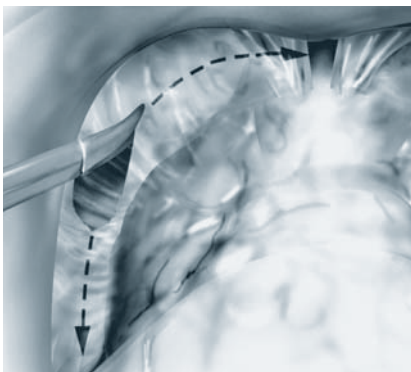


Fig. 1a Dissection of prostate apex

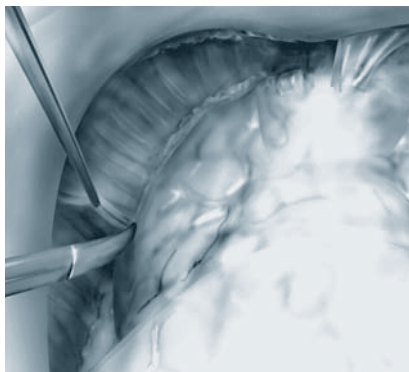


Fig. 1b

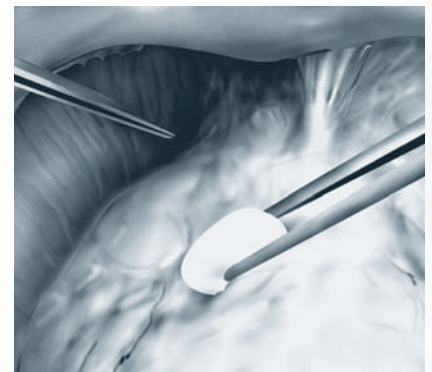


Fig. 1c



## ■ Preservation of the striated sphincter

The striated urethral sphincter is located at the centre of an anatomic unit [9] ("sphincter complex") encased by the dorsal vein complex, lateral pelvic fascia and Denonvilliers' fascia (Fig. 2a). The urethra should not be dissociated from this environment as any dissection isolating an urethral tube from adjoining structures will weaken the sphincter. The sphincter complex is divided in five stages: the superficial then deep part of the dorsal vein complex which covers the sphincter fibres, the ventral then dorsal half of the urethra, and finally Denonvilliers' fascia.

- Stop backbleeding with an x-shaped stitch (absorbable suture 0) over the anterior surface of the prostate.
- Slide the blades of a prostatic retractor (BT680R) along each side of the dorsal vein complex.
- Clamp the dorsal vein (15°-angled clamp EF167R) over only 1.5 cm to be above the striated sphincter. The remaining dorsal vein complex covering the sphincter fibres should be below the clamp. [Fig. 2b].

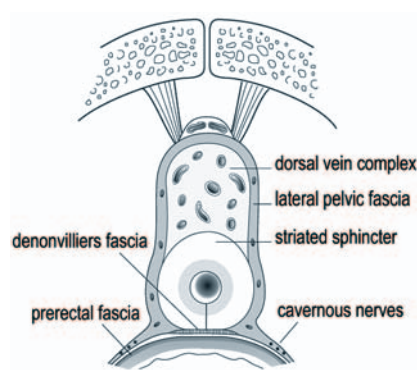


Fig. 2a Beginning of dorsal vein complex section

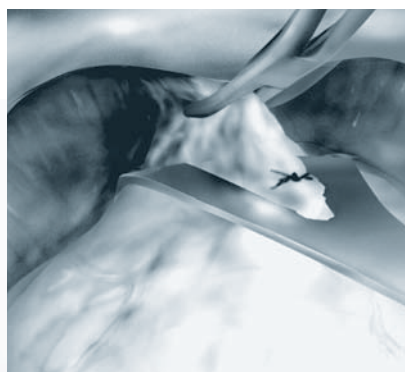


Fig. 2b



# Barré-Instruments

## Preservation of the striated sphincter

- Divide the dorsal vein complex with a sharp surgical knife (BB176R - BB178R) [Fig. 2c]. When two thirds of the section is complete, displace the prostatic retractor a few centimetres back against the anterior surface of the prostate. Exert gentle pressure on the retractor to obtain a horizontal urethral plane and thus good exposure [Fig. 2d, 2e].
- Control bleeding by a continuous U-shaped suture behind the clamp [Fig. 2f].
- Divide the remaining part of the dorsal vein complex and the lateral pelvic fascia covering the front and sides of the sphincter with an angled scalpel with a rounded blade. Start the incision medially and proceed towards the lateral pelvic fascia until 1 mm from the prostate apex [Fig. 3a].

The incision should be made with great care and stop as soon as the muscle fibres are visible. The roof of the sphincter, with its fibres moving up towards the prostate apex, should now be perfectly exposed.

Make a crown-shaped 4/0 running suture on the dorsal vein complex and on each side of the lateral pelvic fascia [Fig. 3b].

- Divide the urethra at 1 mm from the apex, down to the catheter, leaving a little muscle over the apex [Fig. 3c, 3d].
- Grab the urethral catheter with forceps and bring its distal end into the surgical field. Clamp, then cut the catheter to provide traction.
- Remove the prostatic retractor and place a urethral retractor to expose the urethra. Gently push the prostate backwards and tighten the urethral mucosa.

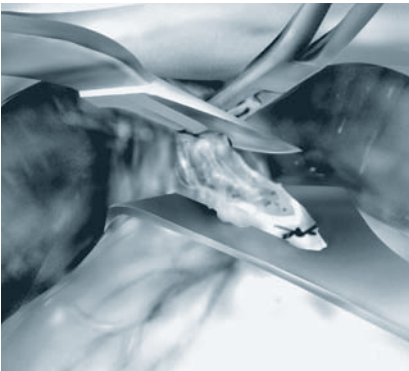


Fig. 2c

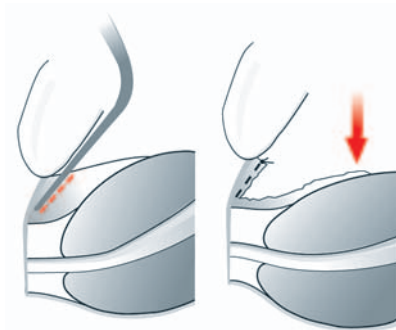


Fig. 2d

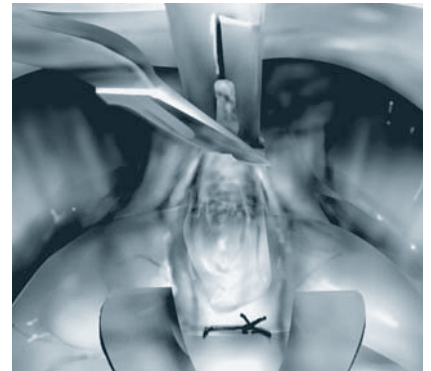


Fig. 2e

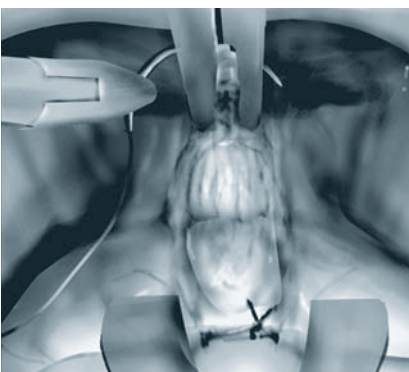


Fig. 2f

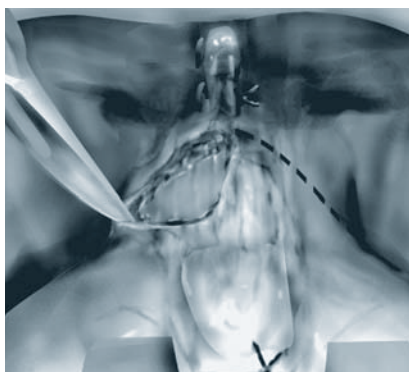


Fig. 3a Completion of dorsal vein complex section and anterior sphincter section

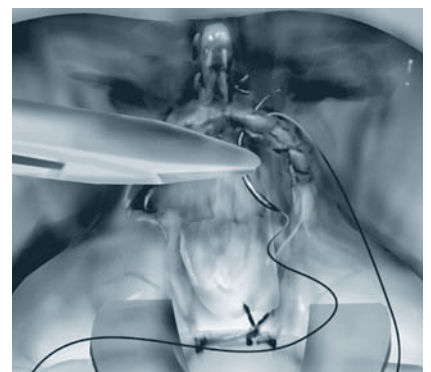


Fig. 3b



Place 3-0 absorbable sutures as landmarks on the anterior edge of the urethra in anticipation of anastomosis [Fig. 3e]. Gentle traction on the retractor straightens the urethra and exposes the urethral mucosa buldges over the posterior sphincter fibres.

- Divide the urethral mucosa, submucous chorion, and smooth muscle (of variable thickness) with a pointed blade, by tracking the posterior striated fibres of the sphincter (Fig. 4a). Once divided, they slide over the plane of the striated fibres and retract. The fibres are shaped like a "U" with the bottom of the "U" inserted in Denonvilliers fascia.
- Divide the posterior sphincter fibres of the prostate apex with a rounded blade. This must remove the superficial layers of Denonvilliers' fascia to which the sphincter fibres are attached [Fig. 4b].

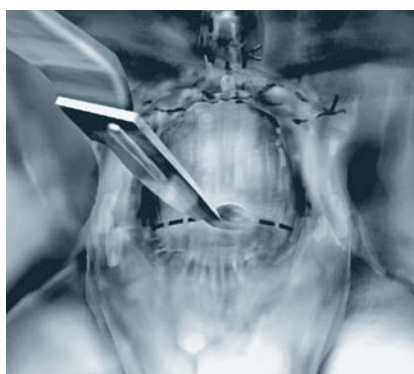


Fig. 3c

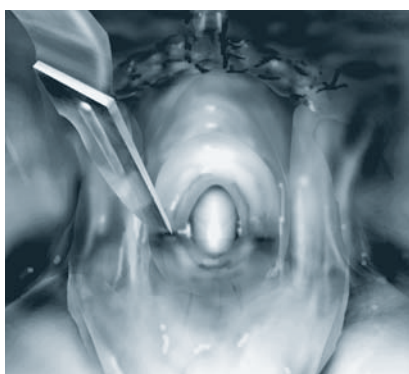


Fig. 3d

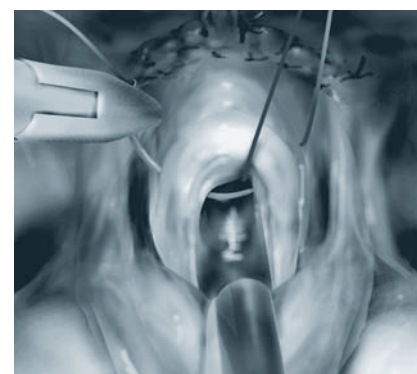


Fig. 3e

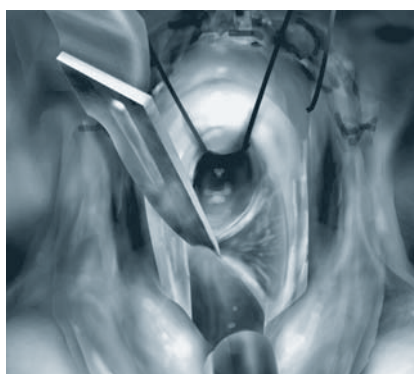


Fig. 4a Posterior sphincter section

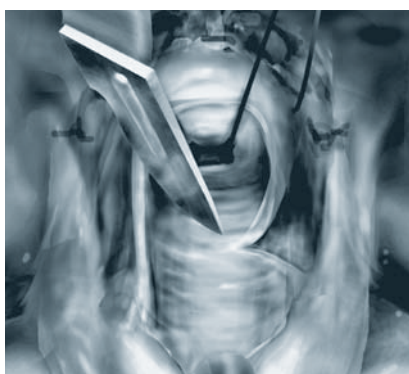


Fig. 4b

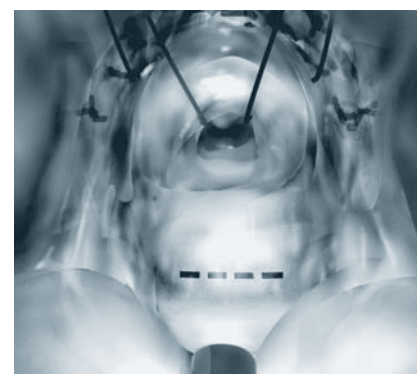

Fig. 4c

In cases of posterior overhang [10], follow the contours of the prostate apex with care.

- Incise the remaining layers of Denonvilliers' fascia transversally with a pointed bistoury, a few millimeters from the apex, in a narrow midline position in order not to injure the nerves located laterally [Fig. 4c].
- Expose the median rectal prostate plane with Metzenbaum scissors, leaving the Denonvilliers' fascia on the prostate [11]. If this plane, which is crucial for initiating nerve sparing, is difficult to find, as when Denonvilliers' fascia is stuck to the pre-rectal fascia, free the apex over a few millimetres and then expose the plane.

# Barré-Instruments

## Nerve sparing

The neurovascular bundles run along the vascular pedicles coming from the terminal branch of the inferior vesical artery. As noted by Walsh, the nerves follow the vessels which act as a guide to dissection [1]. However, the vessels do not follow the posterolateral prostate contour in a straight line but curve up its lateral surface. The bundles lie between the parietal and the visceral fasciae (lateral extension of Denonvilliers' fascia) [1] [Fig. 5a]. Dissection should take place in this interfascial space. A thin layer of connective tissue should be left on the prostate to prevent the risk of positive margins, especially in cases of unsuspected focal extracapsular extension (ECE) [12,13]. The visceral fascia should be present on the excised specimen. Although it is easier to preserve the bundles intact by intrafascial dissection, this is not recommended as there is a high risk of positive margins from dissection in contact with gland tissue [Fig. 5a].

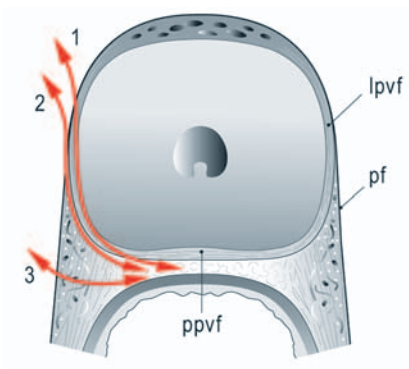


Fig. 5a Surgical anatomy of prostate fasciae [23].  
Surgical approach to sparing the neurovascular bundle

- p.f.** parietal fascia or levator ani fascia
- l.p.v.f.** lateral prostate visceral fascia
- p.p.v.f.** posterior prostate visceral fascia or Denonvilliers' fascia

- Arrow 1** intrafascial dissection
- Arrow 2** interfascial dissection
- Arrow 3** extrafascial resection

### There are two nerve-sparing techniques:

- **Antegrade dissection** [Fig. 5b] starts at the lateral surface of the prostate [14,16], proceeds along the posterolateral contour, and ends at the posterior edge. There is a degree of uncertainty associated with this technique as dissection can start either above the neurovascular bundle (risk of creating intrafascial dissection) or below the bundle (risk of injury to the nerves).
- **Retrograde dissection** [Fig. 5c] starts at the posterior surface of the prostate. The medial border of the bundle is exposed after the plane between the rectum and the prostate in the midline has been developed.
  - Dissect along the posterolateral surface of the prostate following Denonvilliers' fascia, then the lateral prostate visceral fascia. This exposes and isolates all the prostatic pedicles coming from the neurovascular bundles. The bundles are thus progressively freed from the prostate up to their extremity on the lateral surface.
  - Apply very gentle traction on the urethral catheter and gently roll the prostate over on its side to obtain good exposure of the neurovascular bundles. Use tailor-made nerve-sparing dissector (BJ02R) and scissors (BC715R) for dissection.

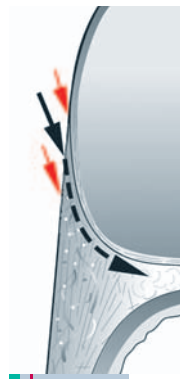


Fig. 5b Antegrade dissection

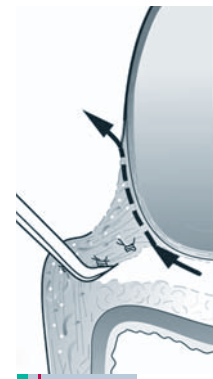
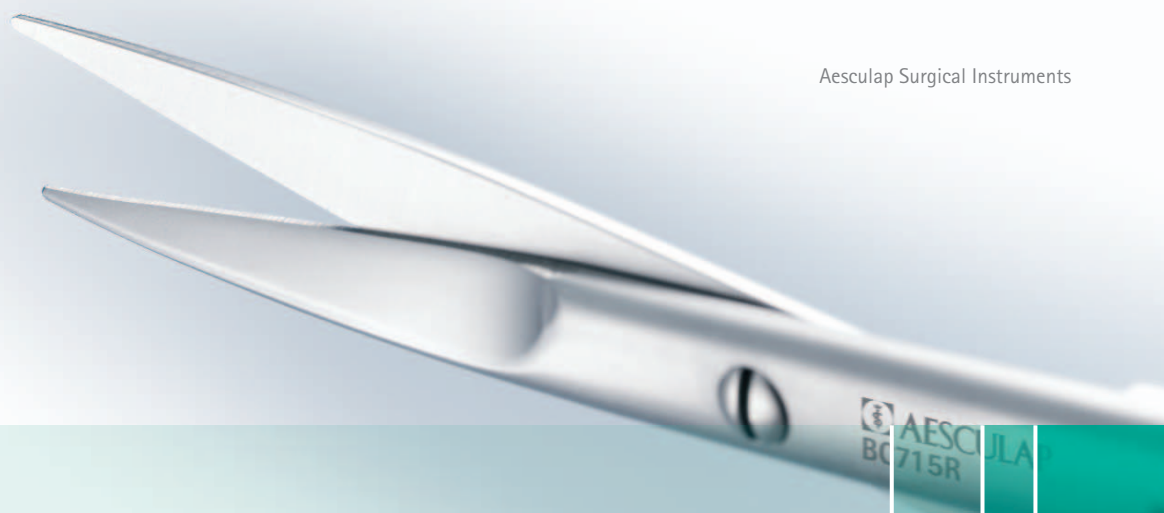

Fig. 5c Retrograde Dissection



### The ease of dissection varies according to prostate zone [Fig. 6a]:

#### ■ Apex [Fig. 6a1b]

The risk of nerve injury is low in this zone as the nerves lie in an external plane. The divided pedicles correspond mainly to the lateral attachment points of Denonvilliers fascia and the levator fibres that were not released when freeing the apex.

#### ■ Mid-gland [Fig. 6 a2c]

This zone holds the greatest risk of injury to the nerves and of positive margins. Free, then incise the parietal fascia overlying the nerve bundle. Expose the small prostate vessels by exerting very gentle traction on the bundle. Isolate each prostatic vessel, millimetre by millimetre, always leaving a thin layer of connective tissue on the visceral fascia. Should the visceral fascia have been inadvertently incised, dissect immediately 1 or 2 mm further away with the tip of fine pointed scissors. Ensure haemostasis with small titanium ligature clips. Because at the top of the curve formed by the vessels, the nerves are in close contact with the visceral fascia, there is hardly any space for dissection. The nerves may sometimes have to be left over 1 or 2 mm to avoid penetrating the visceral fascia. The quality of dissection in the mid-gland zone is critical for early recovery of erectile function and to prevent the risk of possible positive surgical margins. Binocular loops may prove useful but have not been tested.

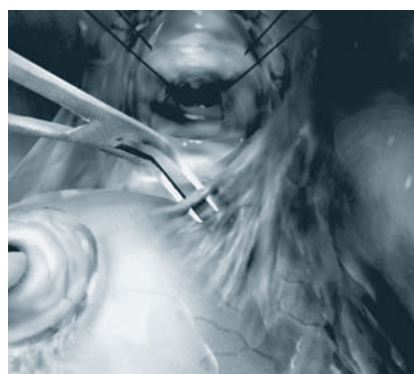


Fig. 6b

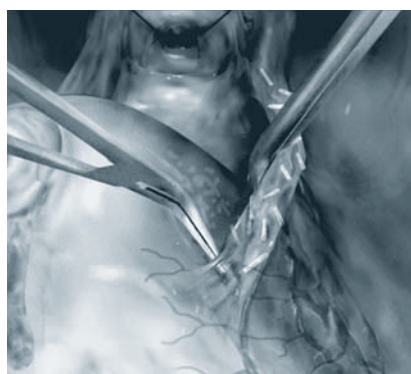


Fig. 6c

#### ■ Base [Fig. 6 a3d]

In this zone, the neurovascular bundle pedicles are further away from the prostate and travel towards the pelvic floor. It is easier to leave some connective tissue when dividing each pedicle.

Dissection ends once the posterior surface of the seminal vesicle, covered with the Denonvilliers' fascia, emerges.

This dissection technique has simplified our indications for nerve-sparing surgery. The decision to resect the neurovascular bundle on the side with a 4 + 3 Gleason score [17] or with a lobe induration on digital rectal examination is always made preoperatively. The decision to resect the neurovascular bundle [18] is made intra-operatively in cases of fibrosis of the prostate fasciae that bar safe dissection and in patients in whom nomograms predict a high risk of capsule breach and in whom insufficient connective tissue can be left for the sake of safety.

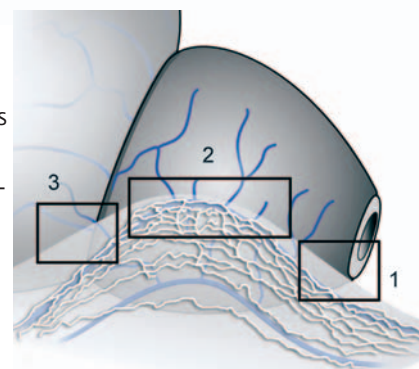


Fig. 6a Three dissection zones:  
a1b apex, a2c mid-gland, a3d base

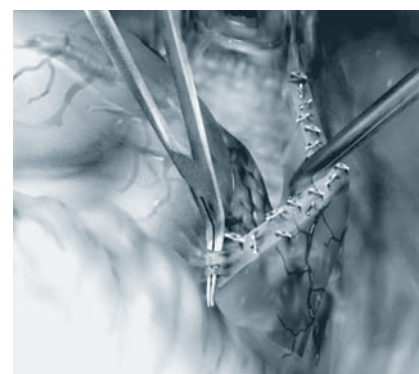


Fig. 6d



# Barré-Instruments

## Dissection of the seminal vesicles and division of the bladder neck

- Divide the thick prostatic base pedicles covering the lateral surface of the seminal vesicle.
- Use forceps to grab the seminal vesicle. Develop the plane between the seminal vesicle and the posterior bladder neck with Metzenbaum scissors, whilst remaining in contact with the seminal plane (Fig. 7a), proceeding as far as possible.
- Interrupt the procedure on the right-hand side. Perform nerve sparing and seminal vesicle dissection on the left-hand side in the same fashion.
- Push back the prostate to expose the posterior surface of the seminal vesicles. Insert a dissector inside the seminal vesicles/bladder neck plane, leaving a surgical loop as a landmark [19] [Fig. 7b].
- Push the prostate towards the lower part of the surgical field.

- Divide both lateral vesicoprostatic junctions using the tightened surgical loop as a guide (Fig. 7c). Each division starts with the retrovesical fat and comes gradually into contact with the posterior surface of the bladder neck. Join up both divisions on the anterior surface of the bladder neck.
- Perform the anterior vesicoprostatic division, leaving a thin layer of bladder tissue on the prostate base to avoid the risk of positive surgical margins. Proceed with the incision until the Foley catheter is exposed. Incise the posterior bladder neck wall, pushing back a median lobe if necessary [Fig. 7d].
- In cases of high-grade lesions of the prostate base, it is preferable to resect the bladder neck [20,21].

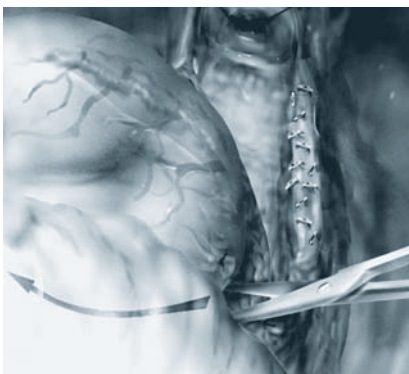
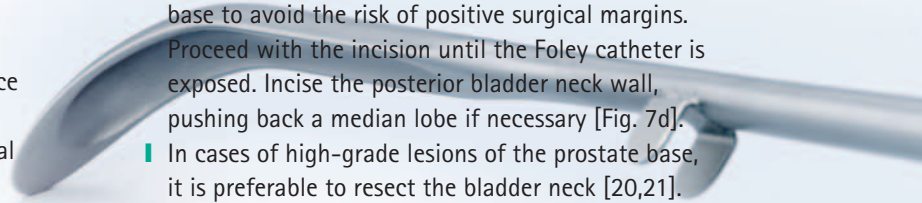


Fig. 7a Dissection of seminal vesicles.  
Bladder neck section.  
Excision of seminal vesicles

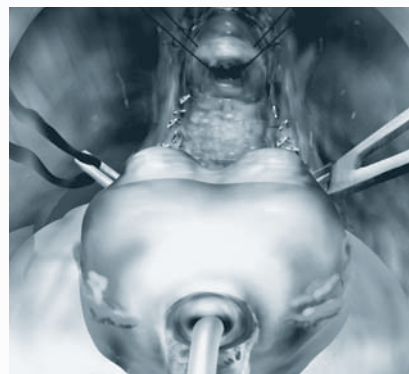


Fig. 7b

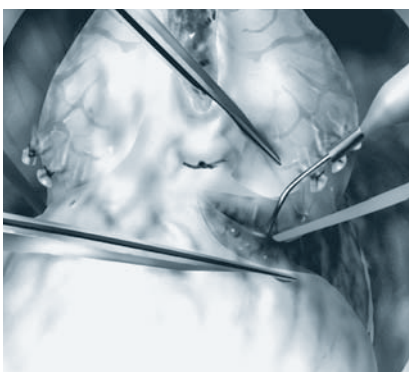


Fig. 7c

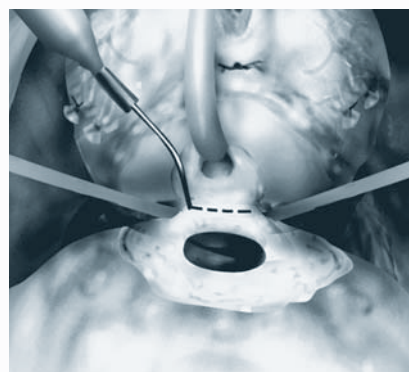


Fig. 7d

## ■ Excision of the seminal vesicles

Traction of the prostate by the Foley catheter exposes the seminal vesicles and the vas deferens covered with the thin anterior sheet of Denonvilliers' fascia [Fig. 7e].

- Transect and ligate each vas deferens as far distally as possible from the prostate.
- Remove the seminal vesicles in their entirety. In most cases, the tip of the seminal vesicles is above the plane of the neurovascular bundles and there is no risk of injury to the nerves. In some cases, it is necessary to tighten the specimen to move the lower extremity of the seminal vesicles away from risk of injury. Dissect in contact with the seminal vesicles, neither too deep nor too wide. This may be a bit awkward but can be done in patients with long vesicles with tips extending beneath the plane of the neurovascular bundles.
- Further haemostasis may be necessary notably on the bladder neck. However, haemostasis near the neurovascular bundles can cause irreversible neurological injury and no coagulation should be performed at this level.

## ■ Visual inspection of the specimen

- Check the quality of the excision macroscopically, paying special attention to the apex. There must be a very small ring of sphincter muscle fibres around the urethra and the Denonvilliers' fascia must be identifiable posteriorly.
- Check that there is a small layer of connective tissue at the posterolateral edge indicating absence of capsular incision.

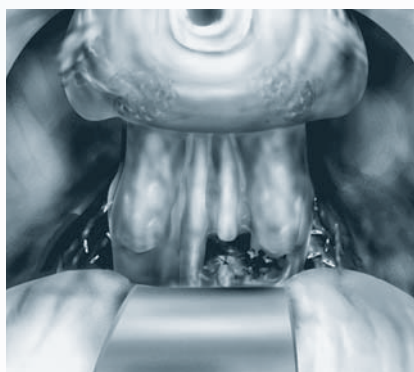


Fig. 7e

# Barré-Instruments

## Vesicourethral anastomosis

- Check bladder neck opening. Use a linear posterior "tennis racket" closure for wide bladder neck openings.
- Insert a CH 16 Foley catheter to locate the urethral lumen before and after each suture passage.
- Tighten both the anterolateral landmark sutures. Place 2 further anterior stitches (3-0 absorbable suture) from the outside in and 5 posterior stitches from the inside out, within a plane anterior to the rectal plane of the neurovascular bundles (22) [Fig. 8a]. Whenever the urethra adjoins the rectal plane, avoid including the posterolateral angle of the urethra by placing 2 stitches on each side, away from the angle.
- Pass vesical sutures and bring the bladder smoothly in contact with the urethra by sliding it along the posterior sutures. Perform urethrovesical stitching. Tie all 5 posterior stitches on the inside in a tensionless knot [Fig. 8b].
- Join the edges together without excessive tension to prevent tearing or ischemia of the sphincter. Insert the urethral catheter and inflate the balloon. Tie all five posterior stitches on the inside in a tensionless knot (Fig. 8b).
- Join the edges together without excessive tension to prevent tearing or ischaemia of the sphincter. Insert the urethral catheter and inflate the balloon. Tie all four anterior sutures. Check that the anastomosis is watertight by filling the bladder with 120 cc saline.
- Position a suction drain on the anterior surface of the bladder, avoiding direct contact with the anastomosis. Perform a conventional closure.




Fig. 8a Urethrovesical anastomosis

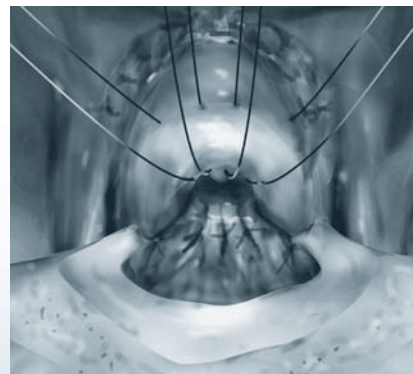


Fig. 8b Urethrovesical anastomosis



## References

- [1] Walsh P. Anatomic radical retropubic prostatectomy. In: Walsh P, Retik A, Vaughan E, Wein A, eds. *Campbell's Urology*. Philadelphia: Saunders; 1998. p. 2565-88.
- [2] Villers A. Extracapsular tumor extension in prostatic cancer: pathways of spread and implications for radical prostatectomy. *Monographs in Urology* 1994;15:61-77.
- [3] Rosen MA, Goldstone L, Lapin S, Wheeler T, Scardino PT. Frequency and location of extracapsular extension and positive surgical margins in radical prostatectomy specimens. *J Urol* 1992;148:331-7.
- [4] Ohori M, Wheeler TM, Kattan MW, Goto Y, Scardino PT. Prognostic significance of positive surgical margins in radical prostatectomy specimens. *J Urol* 1995;154:1818-24.
- [5] Blute ML, Bostwick DG, Seay TM, Martin SK, Slezak JM, Bergstralh EJ, Zincke H. Pathologic classification of prostate carcinoma. The impact of margin status. *Cancer* 1998;82:902-8.
- [6] Walsh PC, Marschke P, Ricker D, Burnett AL. Patient reported urinary continence and sexual function after anatomic radical prostatectomy. *Urology* 2000;55:58-61.
- [7] Barré C, Chauveau P, Pocholle P. Minimal blood loss in patients undergoing radical retropubic prostatectomy. *World J Surg* 2002;26:1094-8.
- [8] Partin AW, Yoo J, Carter NB et al. The use of prostate specific antigen, clinical stage and gleason score to predict pathological stage in men with localized prostate cancer. *J Urol* 1993;150:110-4.
- [9] Barré C, Chauveau P. Prostatectomie radicale rétropubienne. In: *Techniques Chirurgicales – Urologie*. Encycl Méd Chir. 41-295. Paris:Elsevier SAS; 2002. p. 1-14.
- [10] Myers RP. Radical prostatectomy: pertinent surgical anatomy. *Atlas Urol Clin Nth Am* 1994;2:1-18.
- [11] Villers A, McNeal JE, Freiha FS, Boccon-Gibod L, Stamey TA. Invasion of Denonvilliers' fascia in radical prostatectomy specimens. *J Urol* 1993;149:793-8.
- [12] Epstein JI, Pizov G, Walsh PC. Correlation of pathologic findings with progression after radical retropubic prostatectomy. *Cancer* 1993;71:3582-93.
- [13] Quinlan DM, Epstein JI, Carter BS, Walsh PC. Sexual function following radical prostatectomy: influence of preservation of neuro-vascular bundles. *J Urol* 1991;145:998-1002.
- [14] Goad JR, Scardino PT. Modifications in the technique of radical retropubic prostatectomy to minimize blood loss. *Urol Clin Nth Am* 1994;2:65-80.
- [15] Graefen M, Walz J, Huland H. Open retropubic nerve-sparing radical prostatectomy. *Eur Urol* 2006;49:38-48.
- [16] Montorsi F, Salonia A, Suardi N, et al. Improving the preservation of the urethral sphincter and neurovascular bundles during open radical retropubic prostatectomy. *Eur Urol* 2005;48:938-45.
- [17] Sokoloff MH, Brendler CB. Indications and contraindications for nerve sparing radical prostatectomy. *Atlas Urol Clin Nth Am* 2001;28:535-43.
- [18] Villers A, Stamey TA, Yemoto C, Rischmann P, McNeal JE. Modified extrafascial radical retropubic prostatectomy technique decreases frequency of positive surgical margins in T2 cancers <2cm3. *Eur Urol* 2000;38:64-73.
- [19] Barré C, Chauveau P, Pocholle P. Improving bladder neck division in radical retropubic prostatectomy by prior dissection of the seminal vesicles and vasa deferentia. *Eur Urol* 1999;36:107-10.
- [20] Shelfo SW, Obek C, Soloway MS. Update on bladder neck preservation during radical retropubic prostatectomy: impact on pathologic outcome, anastomotic strictures, and continence. *Urology* 1998;51:73-8.
- [21] Marcovich R, Wojno KJ, Wei JT, Rubin MA, Montie JE, Sanda MG. Bladder neck-sparing modification of radical prostatectomy adversely affects surgical margins in pathologic T3a prostate cancer. *Urology* 2000;55:904-8.
- [22] Barré C. Anastomose vésico-urétrale dans la prostatectomie radicale rétropubienne. In: *Techniques Chirurgicales – Urologie*, Encycl Méd Chir. 41-307-E. Paris: Elsevier SAS; 2006. p. 1-7.
- [23] Dubbelman YD, Dohle GR, Schröder FH. Sexual function before and after radical retropubic prostatectomy: a systematic review of prognostic indicators for a successful outcome. *Eur Urol* 2006;50:711-20.
- [24] Montorsi F, Guazzoni G, Strambi LF, Da Pozzo LF, Nava L, Barbieri L, Rigatti P, Pizzini G, Miani A. Recovery of spontaneous erectile function after nerve sparing radical retropubic prostatectomy with and without early intra cavernous injections of Alprostadil: results of a prospective randomized trial. *J Urol* 1997;158:1408-10.
- [25] Myers RP, Villers A. Anatomic considerations in radical prostatectomy. In: Kirby R, Partin AW, Feneley M, Parsons JK editors. *Chapter 71. Prostate cancer: surgical principles and practice*. London: Martin Dunitz; 2006; p. 701-13.

## Author

Dr Christian Barré  
Service d'Urologie  
Clinique Jules Verne  
2-4, route de Paris  
44314 Nantes, France

Tel: +33 (0) 2 51 17 17 50  
Fax: +33 (0) 2 51 17 17 51  
E-mail: christianbarre@hotmail.fr

# Barré-Instruments

■ The performance and progress of open retropubic approach in radical prostatectomy



Radical prostatectomy is one of the standard treatments for localised prostate cancer. However, this surgery is still one of the most difficult in the field of urology because it has to achieve two objectives: reducing positive margins rates and retaining postoperative continence and erectile function. The increasing incidence of prostate cancer at young adults makes these objectives


even more significant. Success in cancer control and function preservation requires a detailed knowledge of surgical anatomy and a rigorous surgical technique. To improve the dorsal venous plexus control and urethral division and to allow a precise interfacial dissection in nerve sparing, Dr. Barré has designed and created specific instruments which considerably simplify the surgical technique.

BT680R

- Prostate retractor
- 360 mm, 14 <sup>3</sup>/<sub>8</sub>"



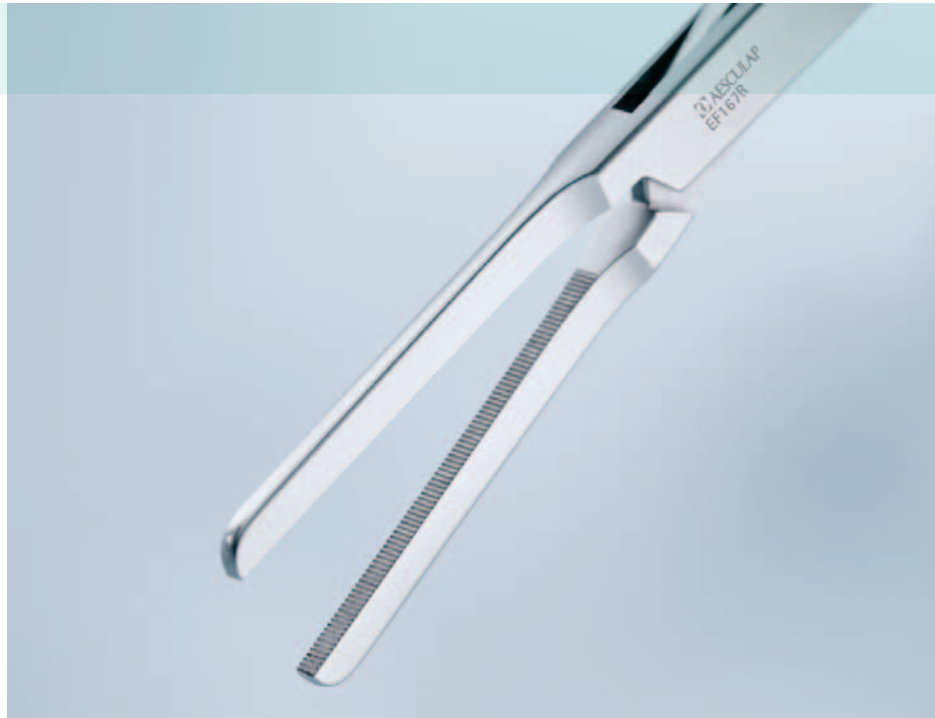BT680R



# Barré-Instruments

EF167R

- Dorsal vein complex clamp
- 210 mm, 8 1/4"



EF167R

BB176R-BB178R

- No. 3 XL
- 250 mm, 10"



12 °

BB176R

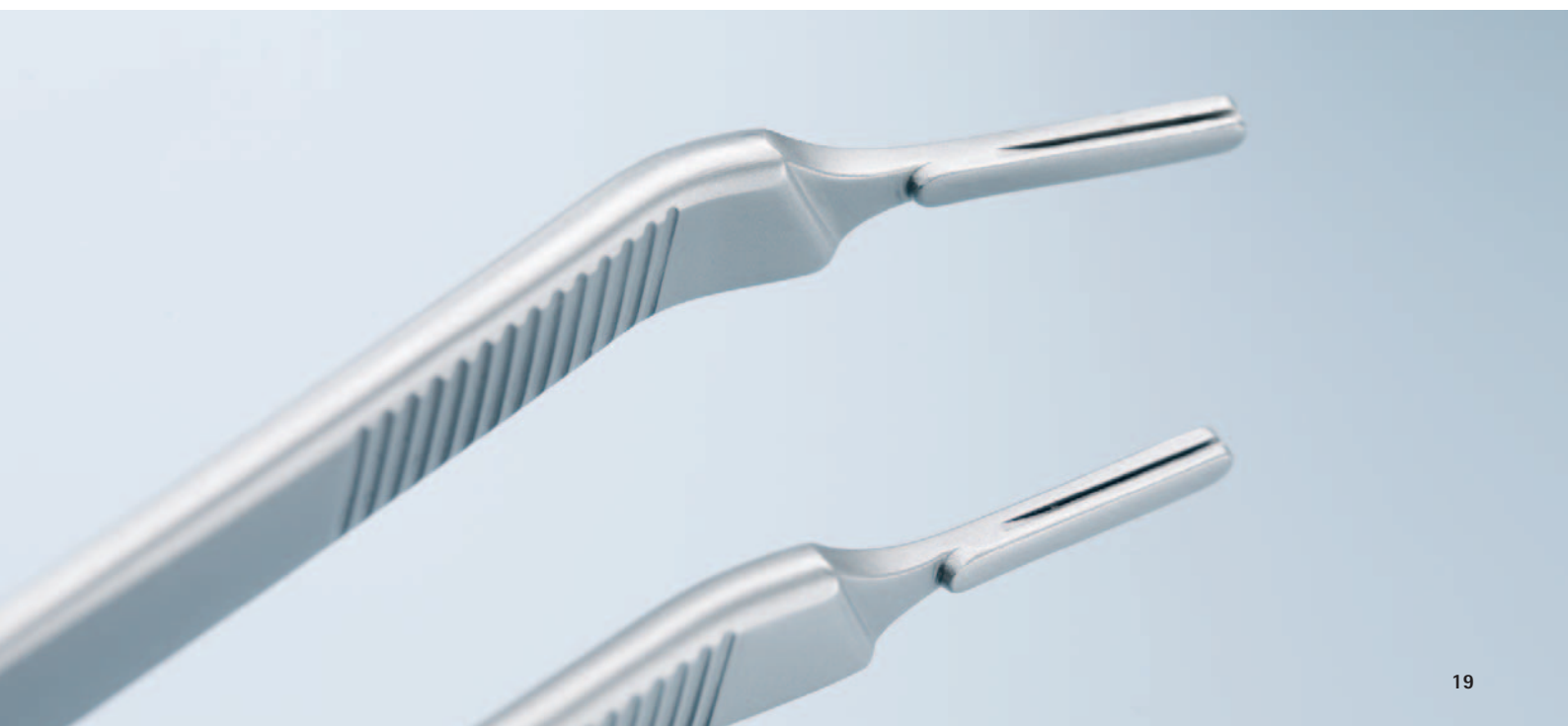

25 °

BB178R



BB177R



# Barré-Instruments

## BT681R

- Urethra retractor
- 390 mm, 15 1/2"



BT681R

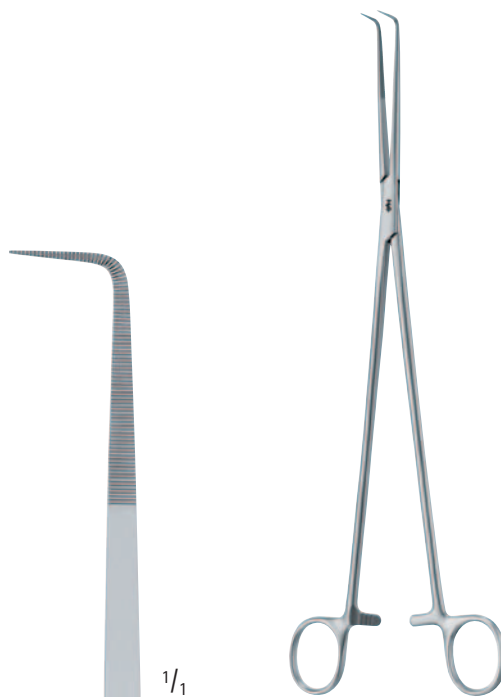

## BJ029R

- Nerve sparing dissector
- 280 mm, 11"



BJ029R






■ BC715R

- Nerve-sparing scissors
- 280 mm, 11"

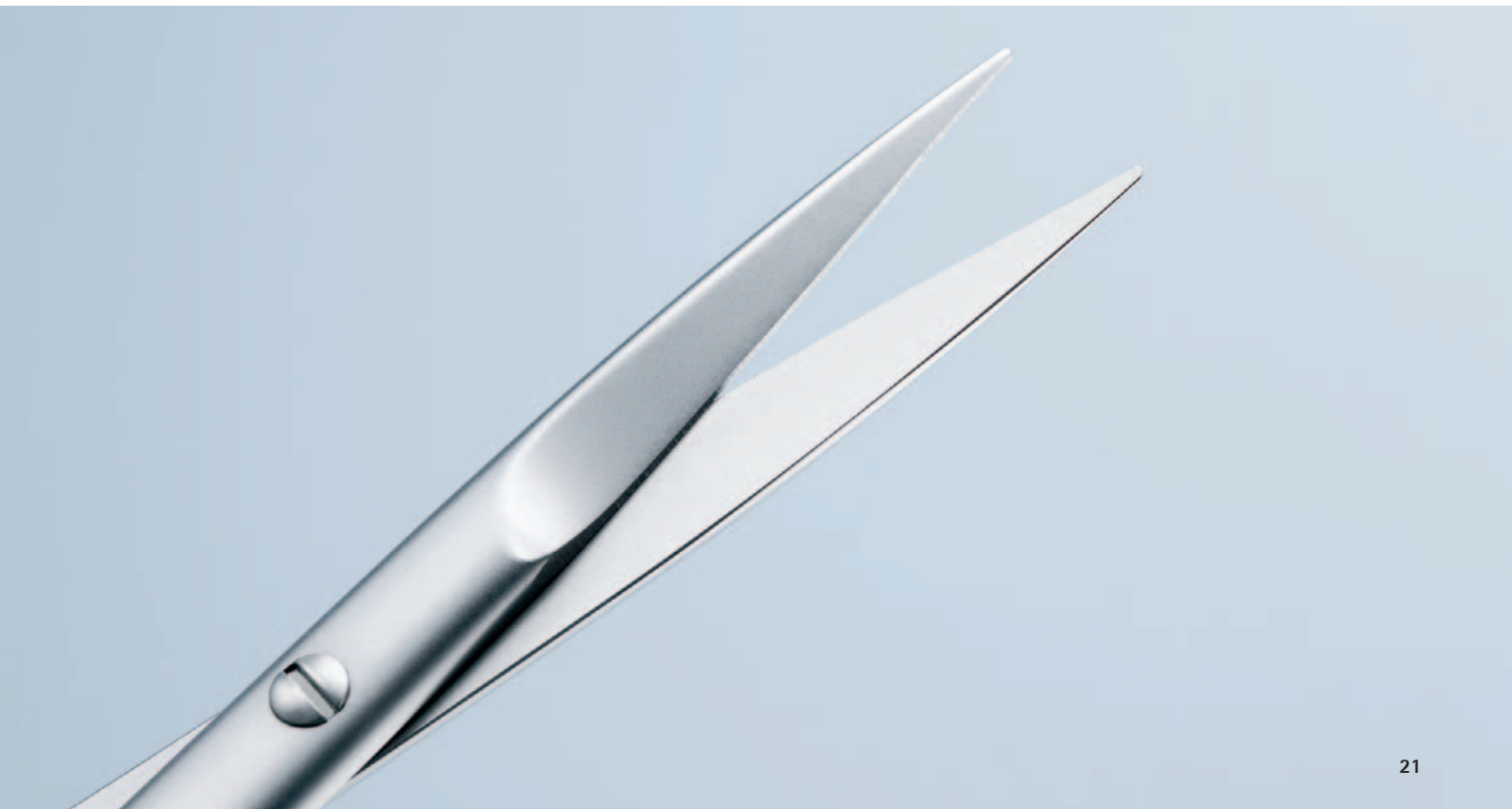sharp/sharp



1/1



**BC715R**



# Barré-Instruments

■ BV927R



BV927R


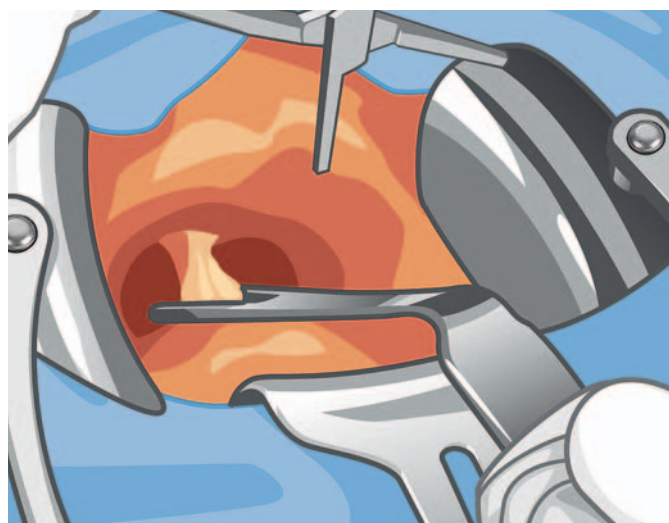


## Barré Prostatectomy Retractor

### BV921R

consisting of:

Quantity	Product code	Description
1	BV922R	BARRÉ Retractor only
1	BV924R	Pair of Blades with ball snap closure, 50 x 70 mm
3	BV849R	Connecting clamps
3	BV840R	Notch rods
1	BV925R	Fiber Light holder, for fiber light carrier OP801R
2	BV926R	Lateral Blade malleable, 190 x 50 mm
1	BV929R	Center Blade, 54 x 70 mm



# Barré-Instruments

■ | BT682R

- Dissecting Hook
- 260 mm, 10 1/4"



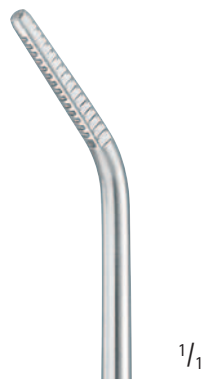1/1

BT682R



■ | BT683R

- Dissecting Hook
- 260 mm, 10 1/4"



1/1

BT683R



# Additional Instruments

## ■ BJ110R

- Nerve sparing dissector
- 280 mm, 11"



BJ110R



## ■ GK685R

- Bipolar forceps
- 260 mm, 10 1/4"



GK685R



# Index

<b>Art. no.</b>	<b>Page</b>	<b>Art. no.</b>	<b>Page</b>
BB176R	19	EF167R	18
BB177R	19		
BB178R	19	GK682R	24
		GK683R	24
BC715R	21	GK685R	25
BJ029R	20		
BJ110R	25		
BT680R	17		
BT681R	20		
BV840R	23		
BV849R	23		
BV921R	23		
BV922R	23		
BV924R	23		
BV925R	23		
BV926R	23		
BV927R	22		
BV929R	23		



# Notice



A large light green rectangular area with horizontal white lines, serving as a notice or comment section. The area is positioned below the 'Notice' header and occupies most of the page's width and height. The lines are evenly spaced and extend across the width of the green area. In the top right corner of this area, there are three small rectangular boxes of increasing teal color, stacked vertically, which likely represent a navigation or status indicator.

Aesculap AG | Am Aesculap-Platz | 78532 Tuttlingen | Germany  
Phone +49 074 61 95-0 | Fax +49 074 61 95-26 00 | [www.aesculap.com](http://www.aesculap.com)

Aesculap – a B. Braun company

The main product mark 'Aesculap' is a registered mark of Aesculap AG.

Subject to technical changes. All rights reserved.  
This brochure may only be used for the exclusive purpose of obtaining information about our products. Reproduction in any form partial or otherwise is not permitted.

Brochure No. C82802

1110/1/3